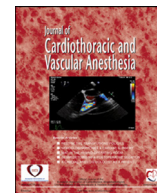


Contents lists available at [ScienceDirect](#)

Journal of Cardiothoracic and Vascular Anesthesia

journal homepage: www.jcvaonline.com

Case Conference

DUPLICATE: Combined Stroke and Spinal Cord Infarction in Hybrid Type I Aortic Arch Debranching and TEVAR and the Dual Role of the Left Subclavian Artery

Hamdy Awad, MD^{*,1}, Arwa Raza, BS[†], Samiya Saklayen, MD^{*},
Sujatha Bhandary, MD[‡], Hesham Kelani, MD^{*},
Ciaran Powers, MD, PhD[§], Eric Bourekas, MD^{||},
Michael Essandoh, MD^{*}

^{*}Department of Anesthesiology at the Wexner Medical Center at the Ohio State University in Columbus, Columbus, OH

[†]Ohio State University College of Medicine in Columbus, Columbus, OH

[‡]Department of Anesthesiology at Emory University School of Medicine in Atlanta, Atlanta, GA

[§]Department of Neurosurgery at the Wexner Medical Center at the Ohio State University in Columbus, Columbus, OH

^{||}Department of Radiology at Wexner Medical Center at the Ohio State University in Columbus, Columbus, OH

The Publisher regrets that this article is an accidental duplication of an article that has already been published, <http://dx.doi.org/10.1053/j.jcva.2021.08.030>. The duplicate article has therefore been withdrawn.

The full Elsevier Policy on Article Withdrawal can be found at <http://www.elsevier.com/locate/withdrawalpolicy>.

© 2022 Published by Elsevier Inc.

¹Address correspondence to Hamdy Awad, 534 Doan Hall, 410 West 10th Avenue, Columbus, OH 43201.

E-mail address: hamdy.elsayed-awad@osumc.edu (H. Awad).